01/2016

Vivano® Spectrum

Convincing case examples of negative-pressure wound therapy.

Abdominal · Traumatic · Special Indication

Editorial details

Published by
PAUL HARTMANN AG, P. O. Box 1420,
89504 Heidenheim, Telephone: +49 7321 36–0,
www.hartmann.info

Issue: 01/2016

Photographs: Jerzy Glowinski (p. 6), Filip Senderak (p. 8), Filip Thieme (p. 10), David Procházka (p. 12), Dominik A. Walczak (p. 14), Dominik A. Walczak (p. 16), Shapovalov Sergei (p. 18), Tomasz Banasiewicz (p. 20), Michal Chlabicz (p. 22), P. Zsoldos (p. 24), Lenka Veverková (p. 26), Heinrich Rotering (p. 28), Emilie Raimond (p. 30), P. Ihle (p. 32), G. Maxant (p. 34), Rui Pedro Borlido Escaleira (p. 36), Joerg Linder (p. 38)
Title: © Markus Burkhardt/Fotograf

The cases in this journal are shown as they have been seen in clinical practice and independently conducted by the responsible health care professionals within their freedom of treatment and in certain cases using the products off-label. They have not been edited by PAUL HARTMANN AG and do not represent clinical recommendations of PAUL HARTMANN AG. The only officially approved use of the products from the VIVANO range recommended by PAUL HARTMANN AG can be found in the respective instructions for use.

Editorial

Dear Colleagues,

Again, it is my great pleasure to introduce the fourth edition of the "Vivano® Spectrum" series. Here you find the first part of the cases presented at the fourth Vivano congress in Stuttgart 2015.

Let me start with a question: did you attend the congress? Then I am glad you came, that you contributed, that you gave input and stimulated discussions! You could not attend? We missed you! Your expertise could have taken the congress even further and you might have brought back home many insights, latest clinical practices in NPWT and most of all experienced a fantastic interactive platform to share ideas, thoughts and questions.

The fourth Vivano congress was truly excellent – this is what participants said. When you looked at the topics it is obvious that NPWT is changing. More reports on many different and new indications in clinical medicine.

NPWT use in open abdomen was discussed in depth and the clinical challenges these patients present raised a lot of interest and lively discussions.

The workshops were hands-on, participants could practice. The program was an ideal mix between lectures and hands-on training designed to combine clinical expertise, knowledge dissemination and practical training.

Participants were enthusiastic, maybe, you join next time? I would be glad if you did! Shared knowledge is the basis for disseminating best practices, innovation and clinical progress.

Kind regards,

Prof. Dr. med. Hans Smola

Content

NPWT in the treatment wound infection after kidney transplantation

Jerzy Glowinski, Radoslaw Lapinski, Andrzej Guzowski, Radoslaw Kowalewski, Marek Gacko
Department of Vascular Surgery and Transplantation, Medical University of Bialystok, Poland

A 49-year-old male and a 65-year-old female with wound infections after kidney transplantation.

Patient anamnesis

Patient 1 was a 49-year-old, slightly obese (body mass index 32 kg/m^2) male with end-stage renal disease (ESRD) secondary to glomerulonephritis. The kidney was from a deceased donor and had been transplanted into the right iliac fossa. Ureteral anastomosis was performed using the Lich method and supported by a 5F ureteric stent because of a narrow ureteral lumen. Triple drug immunosuppression was applied (tacrolimus, mycophenolate mofetil, corticosteroids). Patient 2 was a 65-year-old female with ESRD secondary to polycystic kidney disease and had undergone 14 months of peritoneal dialysis. The kidney was from a deceased donor and had been transplanted into the left iliac fossa, the right cavity was taken up by the peritoneal catheter. The graft displayed normal function.

Wound anamnesis

In patient 1 on the fourth day post surgery, ultrasound examination indicated a large haematoma around the kidney, which was surgically removed and no active bleeding site was found. Postsurgical progress was initially normal with good graft function. A second complication of a urinary leak occurred on day 12. A conservative approach was followed and the ureteral stent maintained, with complete resolution after 1 week. A subsequent control by ultrasonography (USG) supplemented by computed tomography (CT) showed infected fluid around the bladder. Surgical revision of the wound was performed. Bacterial culture indicated Escherichia coli and Proteus mirabilis. Standard treatment of drainage wash and targeted antibiotic therapy were applied for 2 weeks, without success.
Patient 2 suffered repeated urinary tract infections together with superficial site infection. Bacterial tests indicated Klebsiella pneumoniae ESBL+. The patient received conservative treatment for several weeks. Two months after the primary procedure, the patient was admitted to hospital and wound exploration performed. After 12 days, the patient was discharged in a good general condition. During an out-patient visit 2 weeks later, the patient presented with typical symptoms of an abscess, with pain, redness and fluctuance of the lower left quadrant at the line of the postoperative scar. The C-reactive protein level was 221 mg/mL. USG and CT revealed a large abscess (100 × 60 × 90 mm) in the pelvis on the right side, surrounding and compressing the right aspect of the bladder, extending anteriorly and to the left, connecting with a spherical subcutaneous abscess (34 mm in diameter) near the postoperative wound, with gas bubbles.

Aim of the treatment

The application of negative pressure wound therapy (NPWT) to treat wound infection occurring after kidney transplantation.

Wound treatment

On careful inspection of the wound of Patient 1, fibrin and necrotic tissue were found. Following wound debridement, NPWT was initiated using Vivano, with black foam but no contact layer. This was changed every 2 – 3 days and NPWT was applied for 16 days until healthy granulation tissue developed and bacterial tests were negative. The wound was closed with secondary sutures and postsurgical progress was uneventful. In patient 2, both the superficial and deep abscess cavities were explored and careful debridement performed followed by saline washing. The entire cavity was filled with black foam without a contact layer and NPWT was commenced. Bacterial tests indicated Klebsiella pneumoniae ESBL+ and Enterococcus

faecium HLAR. The dressing was changed every 2 – 3 days and NPWT was applied for 38 days. The wound was closed with secondary sutures and healed properly.

Conclusion

NPWT is an effective method in the treatment of early and late wound healing complications after kidney transplantation.

Patient 1, infected wound before NPWT: Targeted antibiotic therapy for 2 weeks was unsuccessful. Fibrin and necrosis were observed.

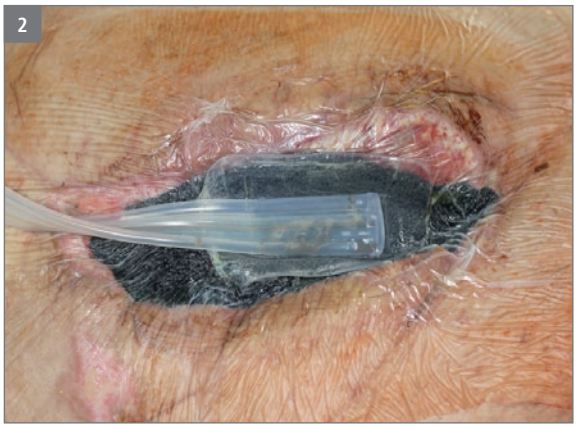

Patient 1, NPWT: Application of NPWT.

Patient 1, completion of NPWT: Healthy granulation tissue is present and bacterial tests are negative.

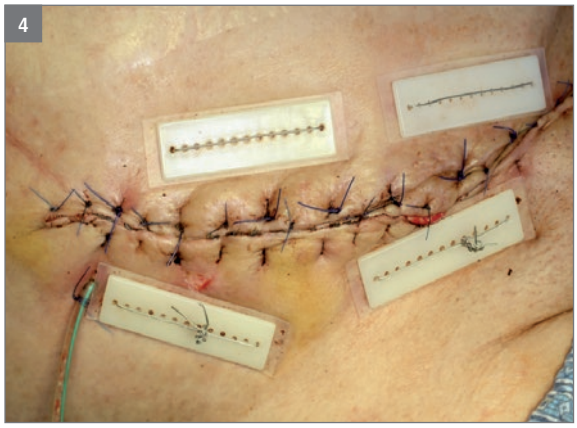

Patient 1, wound closure: Secondary sutures are applied and the postsurgical progress was uneventful.

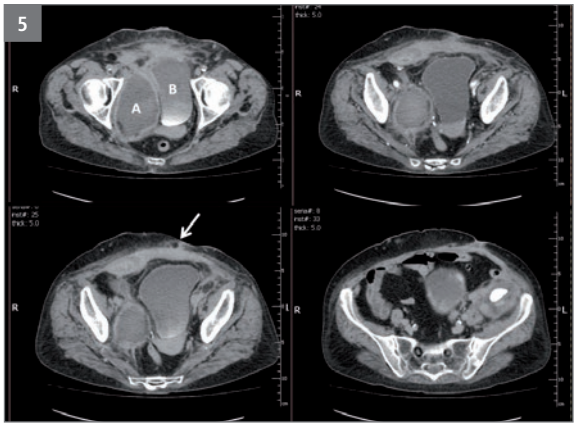

Patient 2, CT observation: A large abscess in the pelvis on the right side surrounds and compresses the right aspect of the bladder, extending anteriorly and to the left, connecting with a spherical subcutaneous abscess near the postoperative wound, with gas bubbles present.

Treatment of abdominal-wall abscess with NPWT in a patient diagnosed with two cancers

Filip Senderak, Piotr Wałęga
Third Department of Surgery, Jagiellonian University Collegium Medicum, Cracow, Poland

A 66-year-old female with an abscess and fistulae of the abdominal wall who was newly diagnosed with breast cancer and who had previously been treated for endometrial cancer.

Patient anamnesis

A 66-year-old female was receiving initial chemotherapy doses for cancer of the right breast and had undergone a total hysterectomy with lymphadenectomy of the pelvis minor for endometrial cancer 5 years earlier. Treatment was suspended due to active cutaneous fistulae.

Wound anamnesis

Three cutaneous fistulae with purulent exudate were present on the abdomen. Ultrasonography / computed tomography (USG/CT) of the abdomen suggested a concentration of fluid of 20 – 28 × 7 × 3 cm beneath the scar from the earlier hysterectomy. Initially, a small piece of the scar, including the fistulae, was removed. An abscess with a large amount of fibrous and infected tissue was found. Methicillin-resistant Staphylococcus aureus (MRSA) was present. The wound was far larger than expected, extending in the subcutaneous tissue below the right ribs, taking up almost one third of the abdomen wall, that the whole hand could be inserted.

Aim of the treatment

Prevent a large-scale surgical intervention including excision of an abdominal wall section by applying negative pressure wound therapy (NPWT), despite contraindications of cancer and a very large wound that was not fully accessible for inspection or initial debridement.

Wound treatment

A decision was necessary regarding the treatment strategy. Contraindications for NPWT were the potential presence of cancer cells within the wound, which could be stimulated by negative pressure application, and being unable to inspect the whole wound or perform an initial debridement. In support of NPWT was the large size and infection of the wound and that long-term "traditional" treatment would require the removal of a considerable section of the abdominal wall, enlarging the wound and thus increasing the treatment period. Moreover, the breast cancer would require aggressive radical treatment. Taking these points into consideration, and personally informing the patient of the risks, it was decided to implement NPWT.
Tissue samples were taken from within the wound for histopathology to check for cancer cells. The largest possible foam piece was inserted within the wound to fill the space completely. Continuous NPWT was commenced, with a negative pressure of 95 mmHg. Because this was the first patient treated by NPWT, a lower pressure was initially applied as a precaution. On the first day, there was a complication of pump-induced bleeding from a small arterial vessel. The treatment was divided into two periods of 18 days, with eight dressing changes, and 10 days, with four dressing changes, the changes being every 2 – 3 days, and with a continuous negative pressure of 90 – 140 mmHg. Extracting the foam was considered to be a form of debridement, with debris removed on each foam change. During a break of 32 days, the patient had left the clinic and was prepared for a mastectomy. The second period of NPWT was resumed immediately after surgery, on the same day. Healing progressed well, with the formation of some new, bleeding tissue within the wound. On completion of NPWT, the patient returned to chemotherapy to complete the treatment. The remaining superficial wound was left to heal by granulation because the patient wished to be discharged without further wound treatment, regarding its condition to be sufficient. The wound had closed with no space re-

maining under the skin. No cancer cells were found in the wound bed and MRSA was absent from two separate samples taken during the procedure. There were no complications reported in the 1-year observation and no reoccurrence was found in USG of the abdominal wall.

Conclusion

Despite the contraindications, the application of NPWT proved successful. Therefore, initial contraindication need not necessarily rule out NPWT; rather, the pros and cons should be considered for each patient in order to achieve full treatment options and to improve the patient's quality of life.

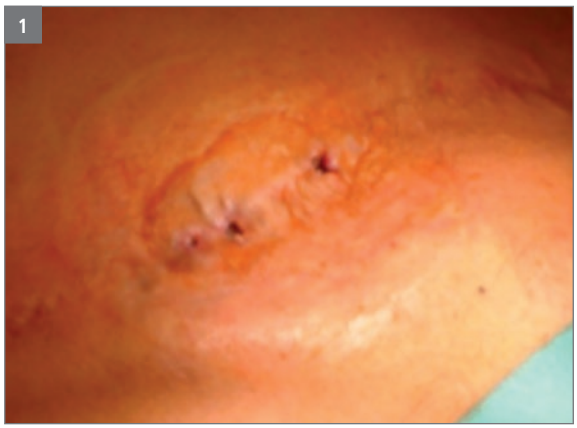

Scar from previous hysterectomy: Three active cutaneous fistulae with purulent exudate on the abdomen. Fluid present under the scar, with a volume of 20 – 28 × 7 × 3 cm, by USG/CT.

Initial intervention: Removal of a small piece of the scar, including all three fistulae. An abscess with a large amount of fibrous and infected tissue, with MRSA, is present.

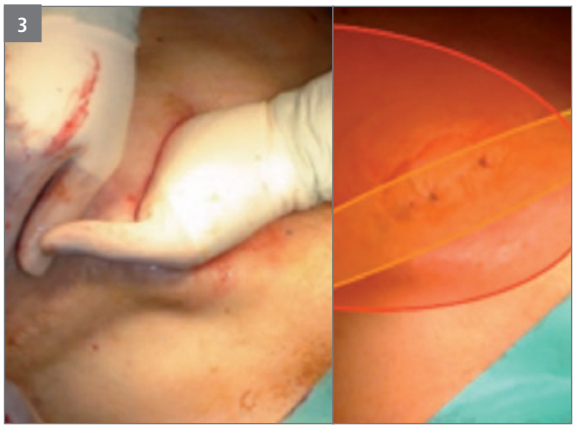

The unexpected: The wound is far larger than expected. A whole hand can be inserted into the abscess, which extends below the right ribs. The yellow region is the expected size, the red region the actual size.

Application of NPWT: Initially applied at a cautious negative pressure of 95 mmHg because this was the first patient to be treated using this procedure. During the whole treatment, over two separate periods, a continuous negative pressure of 90 – 140 mmHg was applied.

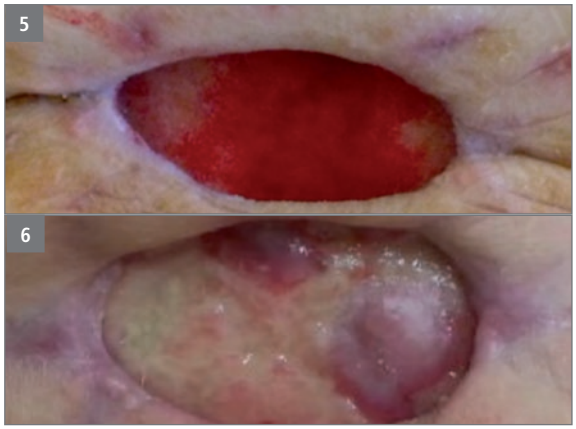

5) Healing: With time, new, bleeding tissue is formed in the wound.
6) Completion of treatment: Once NPWT was completed, the patient returned to complete chemotherapy. The patient requested to be discharged and the wound was left to heal by granulation. There is no longer any space under the skin, with no cancer cells found in the wound bed and no indication of MRSA.

NPWT in patients after solid organ transplantation

Filip Thieme, Libor Janousek, Jiri Fronek
Department of Transplant Surgery, Institute for Clinical and Experimental Medicine, Prague, Czech Republic

Retrospective analysis of wound healing in patients after solid organ transplantation treated with and without negative pressure wound therapy (NPWT); presenting one case with NPWT.

Aim

To evaluate the effectiveness of NPWT retrospectively in a group of patients following liver, kidney and pancreas transplantation.

Patients and treatment

2189 organs were transplanted between January 2009 and December 2014. Of these, approximately 2.5% of patients displayed problems following the surgery, requiring secondary wound healing. These patients were divided into two groups; those who received NPWT (Group 1; n = 30) and those who underwent conventional wound care, including, inter alia, with Hydrosorb, Nu-gel, Tegasorb, Actisorb, bandage with DebriEcaSan (Group 2; n = 26). Most patients in both groups underwent renal transplantation, although there was also a large number who received pancreatic transplantation alone or in combination with another organ because this is a difficult organ to transplant and patients often suffer post-transplantation pancreatitis, with wound healing problems arising from the activation of destructive pancreatic enzymes.

Results

The mean durations of both hospitalisation and healing of the patients of Group 1 of 41 days and 16 days, respectively, were statistically significantly less than Group 2, of 48 days and 27 days, respectively (both, $p < 0.01$). Re-suturing was performed for a slightly higher percentage of Group 1, with one less mortality, although in both cases not significant. NPWT involved a mean of 4.7 cycles, each of a mean duration of 3.9 days.
This study had limitations in that it was not possible to randomise the patients, such that the groups were heterogeneous. The patients had different performance statuses before transplantation, with some being extremely ill. Some patients developed sepsis, which is significantly damaging to wound healing.

Patient anamnesis

A female with type I diabetes mellitus was indicated for simultaneous pancreas and kidney transplantation.

Wound anamnesis

The pancreas was introduced retro-abdominally into the iliac cavity After 20 days post-surgery, the pancreas had to be explanted due to severe liponecrosis of the subcutaneous tissue. After explantation, the wound was still dehiscent and there was demarcation of the liponecrosis.

Aim of the treatment

Application of NPWT to aid healing of a dehiscent and liponecrotic wound following explantation of a failed transplanted pancreas.

Wound treatment

NPWT was applied for 19 cycles and the total hospital stay was 147 days. Drainage was used to apply antiseptic fluid to accelerate the treatment. After the final NPWT cycle, the wound was clean and covered with both granulation and epithelialisation.

Conclusion

The application of NPWT for patients with difficult wound healing after organ transplantation can accelerate the healing process and help to reduce costs through a shortened hospital stay.

1

n=2189 Tx	Group 1	Group 2
TxR	11	9
TxL	4	2
TxP	6	8
TxP+R	8	7
TxL+R	1	0
Overall	30	26

Treatment groups: Group 1: NPWT; Group 2: conventional wound care. A total of 56 patients with problematic wounds requiring secondary healing were included from 2189 transplantations. TxR: renal transplantation; TxL: liver transplantation; TxP: pancreas transplantation; TxP+R: simultaneous pancreas and renal transplantation; TxL+R: simultaneous liver and renal transplantation.

2

1/2009-12/2014	Group 1 n=30	Group 2 n=26	p
Duration of hospitalisation	41±27 d (12–145 d)	48±31 d (14–132 d)	p<0.01
Mean healing duration	16±15 d (6–63 d)	27±11 d (12–84 d)	p<0.01
Wound re-suture	90% (27 patients)	84.5% (22 patients)	n/a
Exitus letalis	3 (MODS, sepsis)	4 (sepsis)	n/a
Average cycles	4.7±0.6 (1–19)	n/a	n/a
During of cycle	3.5±0.9 d (1.6–5.5 d)	n/a	n/a

Results: Comparison of groups. d: days; MODS: multiple organ dysfunction syndrome.

3

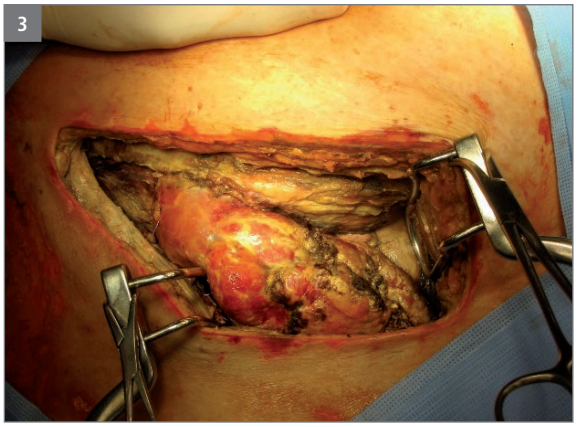

Failed pancreatic transplantation: Transplanted pancreas before explantation, with all the tissue seen here displaying necrosis, together with retroperitoneal necrosis.

4

Post-explantation: Wound after explantation of the pancreas. The wound is dehiscent and there is clear demarcation of the liponecrosis.

5

First NPWT cycle: Drainage is present for the application of antiseptic fluid to accelerate the healing.

6

Final NPWT cycle: 19 cycles were applied in total. The wound is clean, with granulation and epithelialisation.

Treatment of mesh infection following hernia surgery with NPWT

David Procházka
Masaryk Hospital o.z., Usti nad Labem, Czech Republic

Review of 16 patients treated for mesh infection following onlay or sublay hernia surgery.

Patient anamnesis

Sixteen patients of mean age 66 years (range 35 – 82 years), who had undergone onlay (7) or sublay (9) hernia surgery at the hospital or elsewhere between 2010 and 2014.

Wound anamnesis

Patient release after hernia operation was 3 – 4 days, with an infection becoming evident after approximately 10 – 12 days. The patients presented with mesh infection and samples taken for cultivation from the wound secretion indicated that the main pathogen responsible for the infection was Staphylococcus aureus (11), Enterococcus faecalis (5) or a combination of both (4).

Aim of the treatment

The application of negative pressure wound therapy (NPWT) to treat mesh infection following onlay or sublay hernia surgery to save the mesh and to prevent hernia recurrence.

Wound treatment

Empirical antibiotic treatment was commenced, most frequently using ciprofloxacin, amoxicillin or amoxicillin together with metronidazole. After 3 – 4 days, the antibiotic treatment was changed according to the cell culture. Antibiotic treatment was applied throughout the NPWT. The wound was opened under a general anaesthetic, the abscess was drained and the wound was washed repeatedly, normally with Dermacyn or Prontosan. The infected mesh was uncovered, the wound was filled with foam alone and NPWT was applied with a continuous negative pressure of 125 mmHg. Initially, the foam was changed every 2 – 3 days until the mesh was clean and the infection removed. The foam was then changed every 4 – 5 days.

NPWT was applied until the mesh was overlaid with granulation tissue; the mean time was 20 days. The wounds subsequently healed over a mean time of 95 days. In several cases, not all of the mesh became overlaid. The small part of the mesh that was free of granulation tissue was resected and NPWT was reapplied. Once the base of the wound was granulated, NPWT was ceased and the patient was discharged. In total, 65% of the patients were healed, while only 35% developed a recurrence of the hernia.

Conclusion

NPWT should be applied for mesh infection as it provides an opportunity to save the mesh and to prevent recurrence of the hernia. The wound is only re-sutured after complete granulation of the wound is observed.

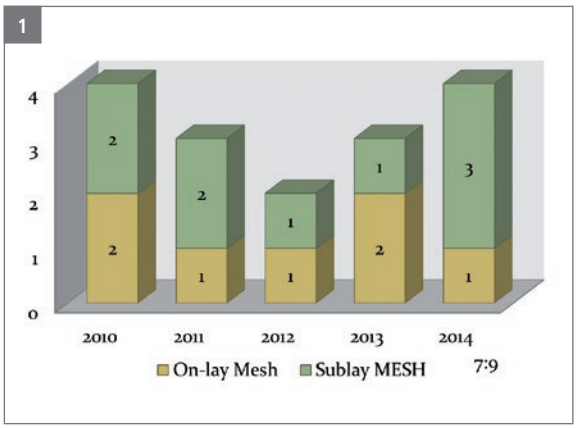

Patients receiving NPWT: Patients presented between 2010 and 2014 with mesh infection following onlay or sublay hernia surgery.

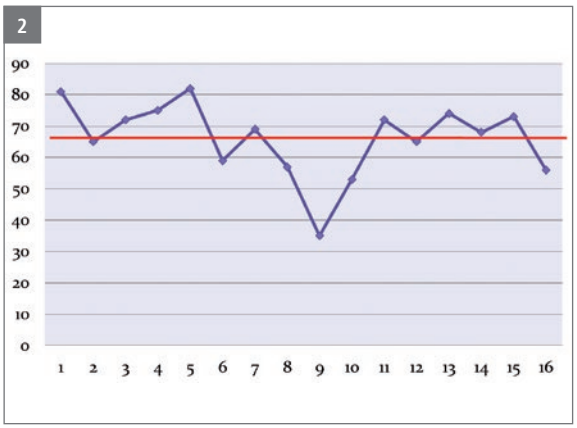

Patient age: Ages of the individual patients. The mean age was 66 years (red line).

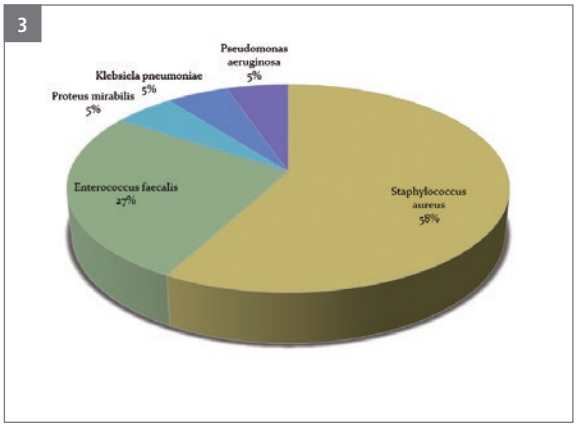

Source of infection: Bacterial species found in cultures of initial wound secretion samples.

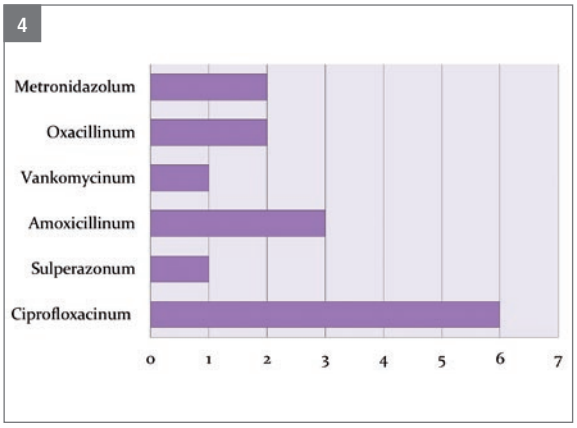

Antibiotic therapy: Antibiotics used initially.

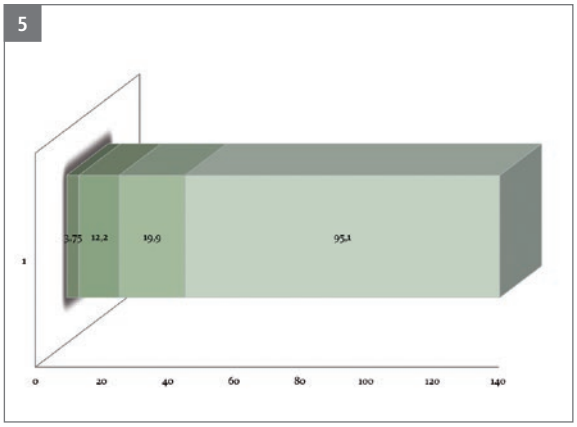

Time line: From left to right: release after hernia surgery; infection becomes evident; NPWT treatment; wound healing.

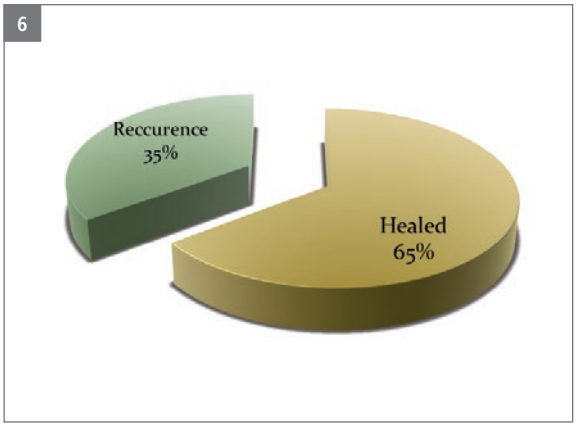

Results of NPWT: Healed wounds vs. hernia recurrence.

Converting an enteroatmospheric fistula to a 'stoma' with NPWT in the open abdomen

Dominik A. Walczak, Rajmund Jaguścik, Wojciech Fałek, Michał Wojtyniak, Piotr W. Trzeciak
Department of General Surgery, John Paul II Memorial Hospital, Belchatow, Poland

A 24-year-old male developed an enteroatmospheric fistula following surgical intervention for acute necrotic pancreatitis.

Patient anamnesis

The 24-year-old male patient with a body mass index of 22 kg/m2, with alcoholism, was admitted with severe abdominal pain, indicating that the injury had been sustained several days earlier.

Wound anamnesis

Laboratory studies showed moderate anaemia and elevated inflammatory markers. Computed tomography suggested haematoma or inflammatory infiltrate between the spleen and pancreatic tail. An emergency laparotomy was performed and partial necrosis of the pancreas was found.

Aim of the treatment

Application of negative pressure wound therapy (NPWT) to convert an enteroatmospheric fistula to a 'stoma' in an open abdomen.

Wound treatment

Necrosectomy of the pancreas was performed and drains introduced for lavage. After 3 days, a repeat laparotomy and necrosectomy were performed, lavage was sustained and the abdominal wound was closed. On re-exploration after 10 days, abdominal wound dehiscence was present, the intestinal loops were covered in granulation tissue and an enteroatmospheric fistula was present in the lower pole of the laparostomy. The wound was classified as grade IV (Björck classification). NPWT was commenced 19 days after admission for 25 days using the VivanoMed Kit and Atrauman Silicone to prevent granulation tissue ingrowth. On the third NPWT dressing change, there was a moderate fistula output of approximately 300 mL and the patient was not receiving any oral solids or fluids. Very dense effluent was clogging the pores, however, causing the intestinal contents to spread beyond both the foam and the drape, making it difficult to keep the dressing airtight and inducing irritation of the wound. To counter this, a hole was made in the centre of the foam, into which three Nelaton drains were inserted and introduced via the intestinal opening. The foam overlying the bowel wall was covered with a hydrofilm drape and was perforated at the drains to allow the removal of exudate. The VivanoTec Port was positioned over the drains to convey the intestinal secretions directly towards the aspiration system and the negative pressure was lowered to 50 – 75 mmHg to prevent the foam cells from closing. The laparostomy was closed step-by-step with each dressing change. By the seventh dressing change, the skin over the laparostomy was closed and a small rotation flap was created, with NPWT continued to improve flap healing. The patient was discharged 16 days after completion of the NPWT, with the enteroatmospheric fistula successfully converted to an enterocutaneous fistula and a stoma pouch could be placed over the fistula.

Conclusion

Adaptation of the NPWT set-up allowed the evacuation of very dense effluent. The enteric fistula in an open abdomen was successfully treated, having been converted from an enteroatmospheric fistula to a 'stoma' using NPWT.

Wound 10 days after repeat laparotomy and necrosectomy: In the wound (grade IV, Björck classification), the intestinal loops are covered by granulation tissue and a fistula is present at the lower pole of the laparostomy (green arrow).

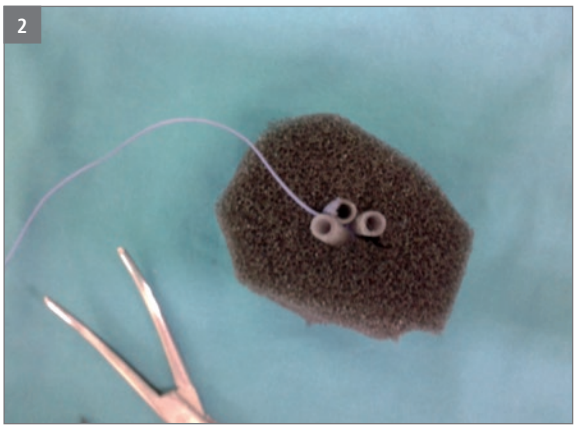

Adaptation of NPWT: To prevent very dense wound effluent closing the pores and thus spreading beyond the foam and drape, three Nelaton drains are inserted through the hole in the central part of the foam to be introduced over the intestinal opening.

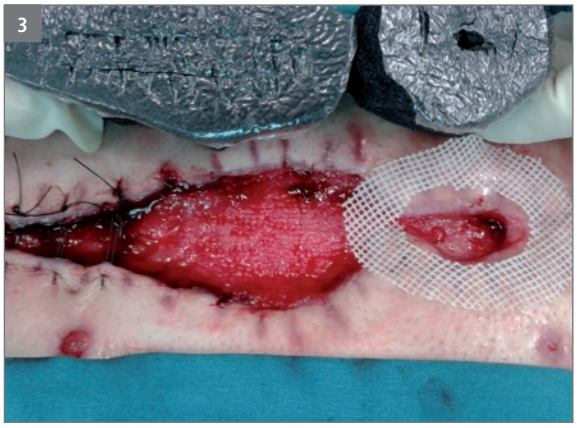

Adaptation of NPWT: Components for removing very dense wound effluent. The foam overlying the bowel wall was covered with a hydrofilm drape and perforated at the drains.

Adaptation of NPWT: VivanoTec Port positioned over the drains to remove the intestinal secretions directly and the negative pressure was lowered to 50 – 75 mmHg to avoid foam-cell closure.

Seventh dressing change: Skin over the laparostomy is closed and a small rotation flap created. NPWT is maintained to improve flap healing.

Discharge: The enteroatmospheric fistula was successfully converted to an enterocutaneous fistula ('stoma') and a stoma pouch can be placed over the fistula.

NPWT using self-made dynamic tension sutures to treat an enteroatmospheric fistula in the open abdomen

Dominik A. Walczak, Rajmund Jaguścik, Wojciech Fałek, Michał Wojtyniak, Piotr W. Trzeciak
Department of General Surgery, John Paul II Memorial Hospital, Belchatow, Poland

A 50-year male developed an enteroatmospheric fistula following surgical intervention for colon cancer.

Patient anamnesis

The patient was a 50-year-old male with a body mass index of 29 kg/m^2 who was admitted with symptoms of mechanical bowel obstruction.

Wound anamnesis

An emergency laparotomy was performed, during which a large tumour of the transverse colon was detected. The patient underwent an extended right hemicolectomy for the tumour.

Aim of the treatment

Application of negative pressure wound therapy (NPWT) to treat an enteroatmospheric fistula in the open abdomen combined with self-made dynamic tension sutures.

Wound treatment

Bowel contents appeared in the drain and wound dressing on the fourth day post-surgery, with symptoms of peritonitis, for which a repeat laparotomy was performed. Leakage from the ileocolonic anastomosis was found. A further anastomosis was performed and the abdominal cavity was cleaned. A loop ileostomy was performed and the skin was temporarily closed for 48 hours due to the lack of an abdominal kit. During a third laparotomy, the intestinal loops were observed to be very swollen. Two intra-abdominal abscesses were removed. The intestinal loops and laparotomy edge were covered with fibrin and the wound was classified as grade IIB (Björck classification). NPWT was commenced 6 days after admission and was applied for 26 days using the VivanoMed Abdominal Kit. The abdominal organ protection layer was adapted, covering the intestinal loops with drape. Black foam was cut to be slightly smaller than the laparostomy and was sutured to the fascia to create limited tension. Negative pressure was applied at 100 mmHg using Vivano. On changing the dressing after 48 hours, a small leakage of the anastomosis was found and the wound was reclassified as grade III. The drain was left for lavage and the laparostomy was reduced. After a further 48 hours, the dressing was changed, slightly altering the set-up, whereby the protective drape was reduced in size to separate the fistula, such that the bowel could adhere to the peritoneum. A second NPWT device was used for active suction of the fistula. After a further 48 hours, a fourth dressing change was performed and the fistula output was very low (50 – 100 mL), there were no bowel contents in the laparostomy, indicating effective suction, and the bowel was coated in granulation tissue. The laparostomy was closed using self-made dynamic retention sutures. These consisted of Foley catheters passed through the abdominal layers with a thread inside to draw the laparotomy edges nearer together and NPWT was applied. After 4 days, the dynamic tension sutures were tightened by cutting the ends of the catheters and inserting new thread to pull the shortened ends of the catheters together. This process was repeated once more and the laparotomy was closed. By the seventh dressing change, the fistula had closed spontaneously after 72 hours of direct active suction. The dynamic tension sutures were removed and the patient was discharged 10 days after completion of NPWT. At the follow-up after 1 month, the wound had healed.

Conclusion

In our first application of NPWT for an enteroatmospheric fistula in the open abdomen, we were able to achieve a successful closure.

Third laparotomy: Wound grade IIB (Björck classification), with swollen intestinal loops, intra-abdominal abscesses and fibrin covering the intestinal loops and laparotomy edge.

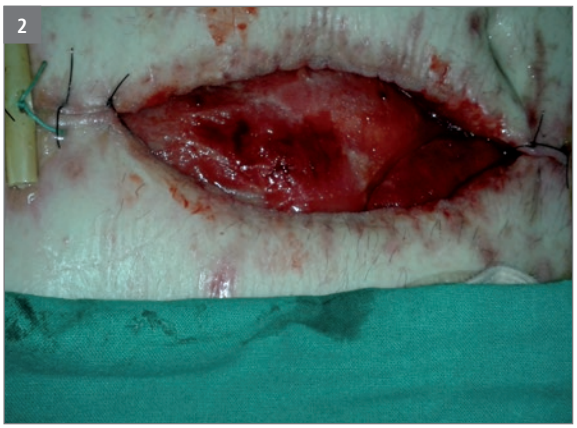

NPWT, second dressing change: Small leakage from the anastomosis. Wound reclassified as grade III. Drain left in for lavage and laparostomy slightly reduced.

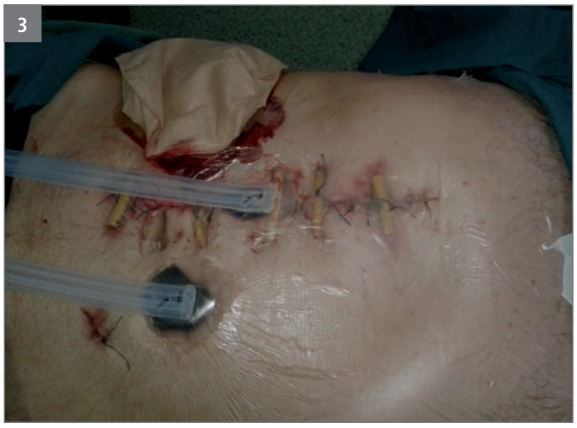

NPWT, third dressing change: Active suction of fistula effluent using a second NPWT device.

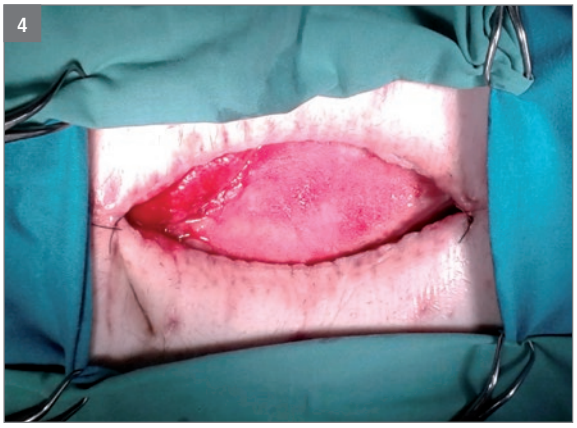

NPWT, fourth dressing change: Low-output fistula, no bowel contents in the laparostomy and the bowel covered in granulation tissue.

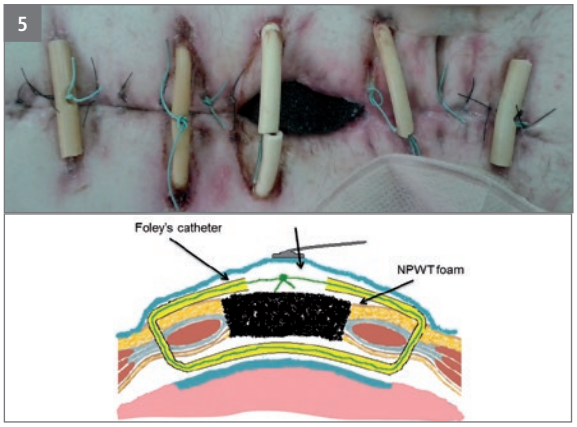

NPWT, seventh dressing change: Showing self-made dynamic tension sutures, with thread (green) within the Foley catheter. Fistula had closed spontaneously.

Patient discharge: Self-made dynamic tension sutures removed and patient discharged from hospital 10 days after completion of NPWT. The suture holes had healed by the 1-month follow-up.

Negative pressure in management of the postoperative abdominal wounds

Shapovalov Sergei, Pleshkov Aleksandr, Panov Arthur, Sukhoparova Elena, Yunusova Yuliya.
The Nikiforov Russian Center for Emergency and Radiation Medicine (St. Petersburg, Russian Federation).

Introduction

Surgeons frequently face complications in operations on the anterior abdominal wall. Their treatment requires significant labor and costs. Commonly, modern technology strategies based on negative pressure wound therapy (NPWT) are applied.

Aim:

To improve the results of the treatment of postoperative abdominal wounds.

Methods:

The treatment algorithm for abdominal wounds defines allocation to two groups: patients with hernias and evisceration (i.e. defects of the musculoaponeurotic layer); patients with abdominal-wall defects without disruption of the musculoaponeurotic corset. Patients in the first group normally present with a damaged parietal peritoneum and exposed internal organs. If it is not possible to eliminate a defect by primary closure, an abdominal kit is used. This is applied until a granulation layer is formed over the viscera, when split-thickness skin grafting is performed (Fig. 1). Vacuum-assisted dressing is also placed over skin grafts to improve graft adaptation and to prevent bruising. Reconstructive surgery to restore abdominal wall integrity is performed during the delayed postoperative period. When abdominal wall suture failure occurs without disruption of the musculoaponeurotic corset, the strategy depends on the estimated defect size. Defects < 8 – 10 cm can be eliminated using local flaps (Fig. 2) or acute dermatension (Fig. 3). In these cases, NPWT is used for preoperative wound preparation and to prevent suture failure during the postoperative period. Defects > 10 cm require flaps with an axial blood supply. Most frequently, we use a pedicled fasciocutaneus groin flap (Fig. 4). In these cases, NPWT is primarily used for preoperative wound preparation and to prevent suture failure during the postoperative period.

Materials:

Twelve patients with different postoperative abdominal-wall defects were observed in our clinic. The period from defect formation to first assessment by a plastic surgeon was 5 – 23 days. The mean patient age was 57.5 ± 14.6 years. According to the above algorithm, three patients with evisceration and nine patients with defects of the abdominal wall without musculoaponeurotic layer damage were treated. NPWT was applied in all of the cases.

Results:

All the observed patients achieved recovery, with healing of the anterior abdominal-wall wounds. In two cases, local inflammatory complications and healing by secondary intention were observed.

Conclusion:

The efficiency of the treatment of the abdominal wall has increased significantly with the availability of negative pressure therapy. The application of NPWT for the preparation of abdominal wounds for delayed closure is the method of choice.

Fig. 1. (42-year-old female):
1 year after skin grafting of a large evisceration.

Fig. 2. (67-year-old male):
a) Postoperative wound after bladder tumor removal.
b) NPWT wound preparation and delayed closure with Z-plasty.

Fig. 3. (69-year-old male):
a) Abdominal wound after hernia mesh repair.
b) NPWT preoperative wound preparation.

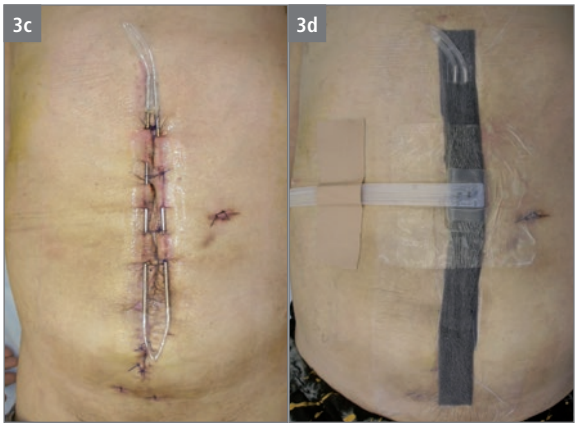

Fig. 3. (69-year-old male):
c) Acute dermatension.
d) Vacuum-assisted suture failure protection.

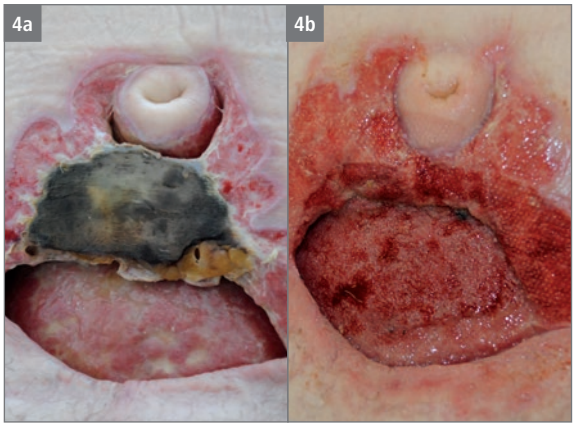

Fig. 4. (38-year-old male):
a) Infected wound after abdominoplasty.
b) After NPWT wound preparation.

Fig. 4. (38-year-old male):
c) Wound closure with pedicled groin flap.

NPWT in complicated abdominal wounds with stomata

Tomasz Banasiewicz
Department of General, Endocrinological Surgery and Gastrointestinal Oncology, Poznan University of Medical Sciences, Poznań, Poland

The application of negative pressure wound therapy (NPWT) for complicated abdominal wounds with stoma. Tips and tricks.

Aim of NPWT application

The application of NPWT in complicated abdominal wounds with stomata follows the "TIME" algorithm in taking care of tissue (T) and removing non-viable tissue, reducing inflammation and infection (I), ensuring a moist environment (M), to provide a good wound environment to improve the healing conditions, and encouraging epithelialisation (E) by good skin care of the abdomen, wound margin and by the stoma. Additionally, NPWT is applied for effective stool evacuation from the stoma to avoid contamination of the wound. Therefore, the distance between the stoma and the wound margin, in order to avoid interference with efficient stoma function, plays an important role in how NPWT is applied. The effluent needs to be accurately measured and costs contained.

Sufficient distance between wound and stoma

To treat the wound and stoma separately, we suggest 5 – 6 cm for the stoma bag to cover the stoma and 3 – 4 cm at the wound margin for the foil, thus a total of 8 – 10 cm. When the stoma is sufficiently distant from the wound, we can concentrate on the wound treatment. The stoma can be covered with a standard stoma dressing, with a stoma bag. With the NPWT, the pad is placed at the point of greatest secretion. Additionally, drain orientation should be chosen to improve the wound and dressing control and should be away from the stoma and patient comfort and mobility should be borne in mind.

Stoma near the wound

When the stoma distance from the wound is too small, stoma paste / silicone gel can be applied to reinforce the inner edges of solid wafers to protect them from melt-out and to establish an improved seal in order to reduce leakage under the foil. Pastes can also be used to smooth uneven surfaces, particularly in obese patients, providing a flat surface for wafer application. Although the size of the stoma bag can be reduced, the nearness of the bag may still result in it being pulled out. Parastomal and silicone rings and stoma pads can be used, the rings creating some distance from the wound and improving stool evacuation.

Other complications and general tips

Even when the distance between the stoma and wound appears sufficient, should the skin between not be flat due to scarring and being inflamed, it is difficult to apply both foil and a stoma bag, and this should therefore be approached as a near-wound stoma. When there is a large amount of secretion, particularly involving a fistula, a dedicated fistula adapter or parastomal ring can be applied and a stoma bag attached. For extremely large amounts of secretion, a stoma bag can be placed on the highest secretion point of the fistula, a drain placed through the stoma bag and the intestinal wall and suction can be applied to improve the evacuation of the liquid stool. This may lead to chronic fistula formation, but that can be treated later, patient survival being the priority. Skin care is crucial for avoiding epithelial dehiscence and because of the possible hesitation of the patient to accept the procedure. Therefore, a skin-safety layer between the foam and skin can be applied. This also prevents ingrowth into the PU foam. In this indication a non-adhesive foil as in the Abdominal NPWT set can be used, but also a silicon contact layer is a good option. The stoma bag should not be left for too long because, when it is very full, it is heavy, which may lead to ineffectiveness of the system. Regarding the type and amount of pressure

in NPWT, this would be applied continuously with a negative pressure of 80 – 120 mmHg, although you should be ready to make modifications depending on the situation. When pressure changes are made, the dressing should be checked several times daily.

Conclusion

The question should not be whether to use NPWT, but rather how to apply it appropriately depending on the condition of the wound and how near the stoma is to the wound. Additionally, we should consider what "tricks" are possible and what other materials could be used.

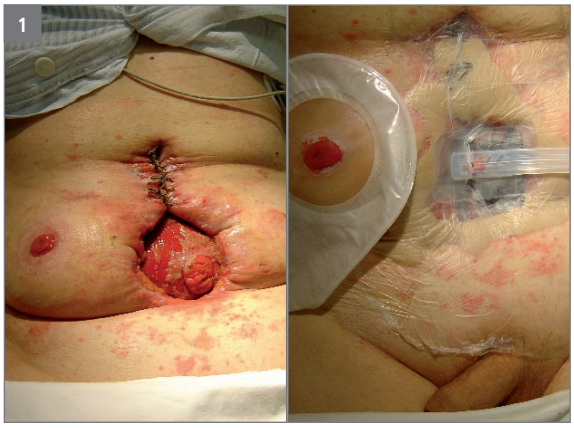

Wound and stoma with sufficient separation: We can concentrate on the wound treatment. The stoma is covered with a stoma bag.

Stoma near the wound: Stoma paste / silicone gel can be applied to establish an improved seal to reduce leakage under the foil.

Poor skin condition, fistula and heavy leakage: Although the actual distance between wound stoma is sufficient, the skin is not smooth and is inflamed, making it difficult to apply the stoma bag and foil. A parastomal ring is used for the stoma, creating distance between the stoma and the wound and improving stool evacuation. However, there is no fluid with the stool at the stoma, because there is heavy exudation from the lower part of the wound with a fistula present. A dedicated fistula adapter or parastomal ring can be applied to the fistula, at the point of the greatest exudation, and a stoma bag applied.

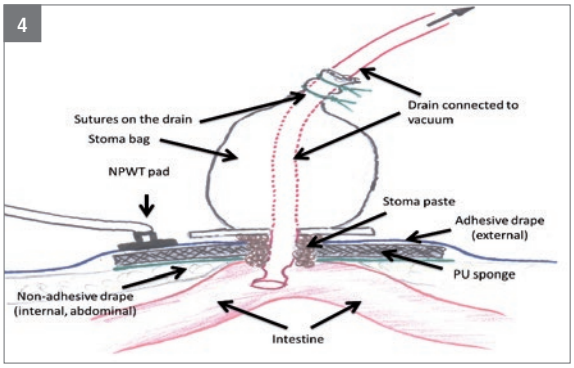

Extremely high secretion: Drainage under vacuum is set up, with a stoma bag placed on the highest secretion point of the fistula, a drain passed through the bag and the intestinal wall and suction is applied to improve the evacuation of the liquid stool.

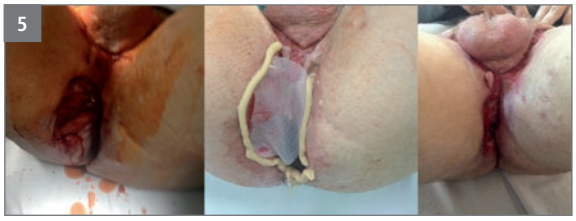

Skin care: The patient has a huge and painful wound. A skin-safety layer is applied between the skin and the foam to prevent epithelial dehiscence and ingrowth into the foam.

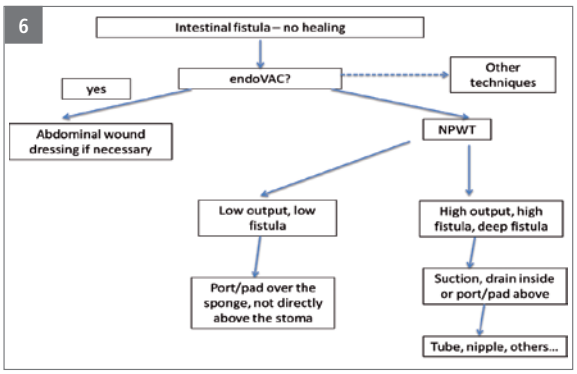

Algorithm when a fistula is present

NPWT in fasciotomy treatment of a popliteal artery injury

Michal Chlabicz
Department of Vascular Surgery and Transplantology, Clinical Hospital of the Medical University of Bialystok, Poland

A 21-year-old male presented with the symptoms of acute left lower limb ischaemia following a knee dislocation.

Patient anamnesis

A 21-year-old male had suffered a left knee dislocation but had refused to be admitted to the orthopaedic ward, did not agree to treatment on the emergency unit and he did not see his general practitioner. After 5 days, the patient complained of knee pain and numbness of the left foot.

Wound anamnesis

No pulse was found for the popliteal artery or below for the posterior tibial and dorsalis pedis arteries. The left foot displayed acute ischaemia and the 6P (pain, pallor, pulselessness, paraesthesia, poikilothermia, paralysis), and ischaemic oedema were present. Computed tomography with contrast medium indicated an occlusion of the popliteal artery. An endovascular procedure was performed because of a suspected dissection of the left popliteal artery. Angiography confirmed an occlusion of the popliteal artery.

Aim of the treatment

The use of negative pressure wound therapy (NPWT) on a difficult healing wound created during a fasciotomy, a limb-saving procedure when used to treat acute compartment syndrome.

Wound treatment

A stent (Supera 5×150) was placed into the dissection of the popliteal artery and another angiography was performed. Stenosis of the tibioperoneal trunk was found, however, which was successfully treated with a second stent (Xpert 5×60). During the period following the injury, the ischaemia and reperfusion syndrome had progressed to compartment syndrome. A fasciotomy was performed to relieve pressure and prevent tissue necrosis. The removal of necrotic muscle tissue was required following the incision. There was a pulse in the popliteal artery and below following completion of the surgery. Debridement of necrotic muscle tissues was performed several times, and Negative Pressure Wound Therapy (NPWT) was applied after each operation. By the fifth week of NPWT, granulation tissue was present throughout the wound. After 1 month of NPWT, a skin graft was performed on this large wound, also using NPWT on the graft. The skin graft had successfully transplanted after 10 days, a split-skin graft being pinkish. Almost the whole skin graft regained full skin integrity and the donor site was healing satisfactorily.

Conclusion

The use of NPWT during the healing of such large wounds as a complication of acute ischaemia appears appropriate. NPWT provides splintage and stability for skin grafts and can evacuate a subgraft collection.

Computed tomography: Contrast agent indicated an occlusion of the left popliteal artery.

Angiography: Confirmed occlusion of the left popliteal artery.

Fasciotomy and debridement: Following fasciotomy, the wound was debrided several times; NPWT was applied after each operation.

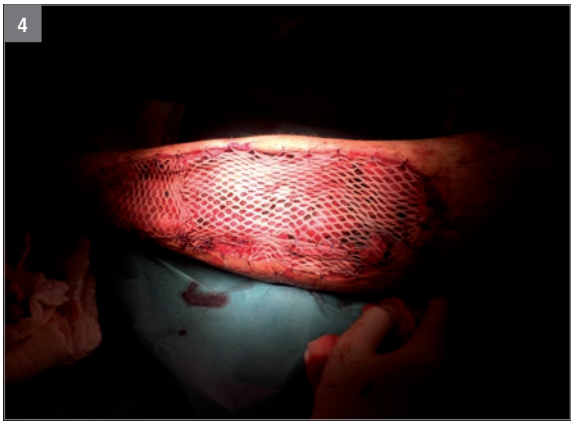

NPWT 1 month: Granulation tissue was present throughout, allowing skin grafting.

NPWT: NPWT applied to the skin graft.

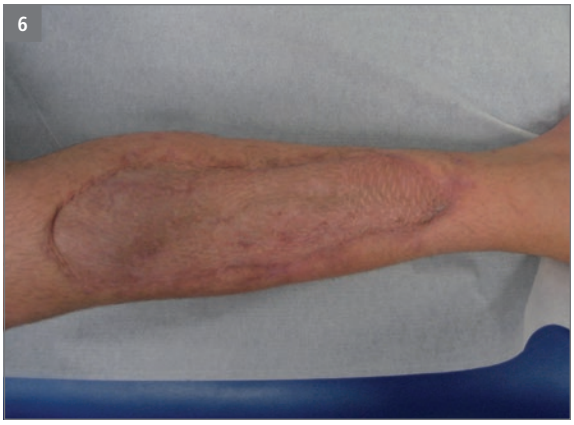

Result: Appearance approximately 3 months after skin grafting.

Negative-pressure wound treatment (NPWT) in conventional therapy-resistant post-pneumonectomy thoracic empyema (PPTE)

P. Zsoldos, D. Szántó, F.T. Molnár
Department of Surgery, St. Sebastian Thoracic Surgery Unit,
Petz Aladár Teaching County Hospital, Győr, Hungary

Patient and wound anamnesis

A 53-year-old male patient developed an indolent thoracic empyema (TE) having undergone a pneumonectomy following neoadjuvant therapy for pT2N2 adenocarcinoma. The immediate postoperative course was uneventful until 3 months later, when he developed post-pneumonectomy TE (PPTE). Thoracic drainage treatment and supportive therapy were initiated and the clinical picture seemed to have been brought under control. Three months later, he was admitted urgently for a full-blown thoracic sepsis. Bronchoscopy excluded bronchopleural fistula (BPF), while an urgent chest CT confirmed the re-accumulation of toxic fluid in the post-pneumonectomy space. Bacteriology confirmed the diagnosis.

Managing plan

1. sepsis management by evacuation of TE and local control by open window thoracostomy (OWT) [fenestration]
2. sepsis control using NPWT
3. space-management using NPWT
4. exclusion of recurrence of the adenocarcinoma
5. space management by omentoplasty

Points of management

Detoxication by evacuation of the post-pneumonectomy space, bacteriological sterilisation of the cavity. Check-up for NSCLC recurrence. Filling the residual space. Supportive treatment (body mass index, protein-rich diet, physiotherapy, psychological support).

Wound treatment

Having explored the thoracic cavity via a general approach, a short segment of rib was removed and a window created. Specimens were provided for microbiological investigation. Following a full-depth debridement and irrigation under hybrid visual and video-assisted surgical control (VATS), the cavity was filled tightly with properly tailored Vivano sponge. Permanent bedside NPWT was applied using intermittent course settings (suction at 120 mmHg for 5 min., followed by 75 mmHg for 3 min. alternating). The cavity was checked and the sponge was changed (specimen taken for bacteriology) every 4 days, using intrathecal narcosis. Antibiotic cover was initiated empirically at the time of the first operation. Parenteral nutrition and enteral protein and carbohydrate administration completed the treatment. Following the second change of the Vivano sponge, the microbiology report was negative. The patient's condition quickly improved as his sepsis was brought under control. As the PP space was sterile and shrunken and the patient's general condition allowed it, a transphrenic omentoplasty allowed the former space to be filled completely on day 21. The patient made a quick recovery and was discharged five days later.
An omentoplasty was performed on day 21 of the treatment, to fill out the rest cavity. The patient has regular check-ups and is well around two years postoperatively.

Summary

In the treatment of chronic empyema, NPWT is still a sort of "off label" methodology, although there are a few pioneers. Evidence is increasing, in numbers and impact, showing this technique to have a role in the complex management of TE. The implementation of NPWT as an important element in the chain of treatment modalities of TE seems to be inevitable. It is safe, quick, patient- and staff-friendly and might provide an advantageous environment for definitive managing steps. Cost benefits and a reduction in the length of hospitalisation should also be taken into consideration.

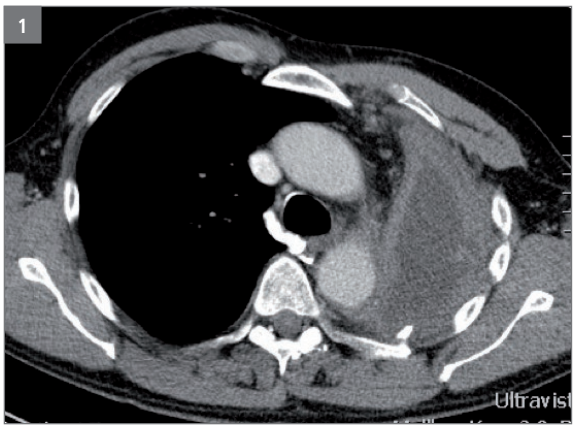

1. Imaging: CT is mandatory before initiating the treatment.

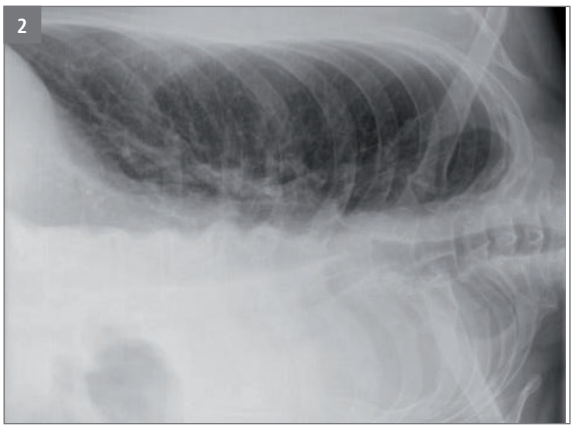

2. CXR following insertion of the sponge.

3. Changing the sponge.

4. Changing the sponge.

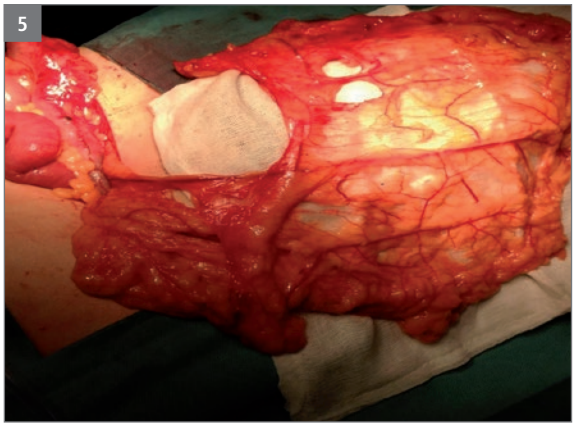

5. Transphrenic omentoplasty.

6. Final check up: CT 3 months following discharge.

Publish or perish; but how to do this?

Lenka Veverková[1], Petr Doležal[1], Michal Nečas[2]
[1]Department of Surgery, Faculty of Medicine, Masaryk University, Brno, Czech Republic;
[2]Consulting HARTMANN, Czech Republic

Availability of a free online database for recording patient information that allows data analysis to aid in publication and to help with both clinical and financial decision-making.

The phrase "publish or perish" is not restricted to academics but also applies to clinicians. Adequate tools are necessary in order to be able to publish. Good hypotheses, theories, reasoning and evidence are needed, with all the related information stored in a database. The database must include the patients' datasets and should enable rapid and reliable access to obtain an overview of different groups of patients and their data, allowing analytical comparisons. Furthermore, the ability to store and analyse financial data provides support for the interaction with the hospital financial department. In order to be able to perform all these tasks, we have developed a new database, now freely available in English at https://en.i-hojeni.cz.

The database

This database is a system for collecting and analysing clinical and economic data with basic medical intelligence functions, thus also acting as an argumentation tool for the hospital finance department, for example, for calculating how much financing a patient will need. Furthermore, it is useful for the effective control of the treatment, for sharing specific case information by the specialists involved in a project and for the presentation of results. When inputting the data, the option is provided as to where to store a new case (outpatient or ward), with an additional section specifically for negative pressure wound therapy (NPWT). A case sheet allows the data for each individual case to be recorded. Images can be stored in order to follow the treatment progress and healing visually. More specialised information related to NPWT treatment, including the duration (commencement and completion dates) and the number of dressing changes, can also be recorded.

Example of use

We have used this database to store the data for 143 patients whom we treated with NPWT and to produce an overview of this data. When it was pointed out that our current spending on NPWT had reduced, we wished to discover the reason. We found that the age and sex did not significantly affect the length of NPWT treatment or the number of dressing changes. Looking at the data on an annual basis, we found that the number of dressing changes had decreased statistically significantly. Therefore, the cost was being reduced through more effective treatment due to an improvement in the learning curve thanks both to wider patient experience and to the availability of the database to help in decision-making.

Conclusion

This user-friendly database is a secure web-based system that will help both to facilitate publications and to provide support for the medical intelligence functions for basic clinical decisions and process and economic determinations.
"Vision without action is daydreaming, dreaming is vision."

1

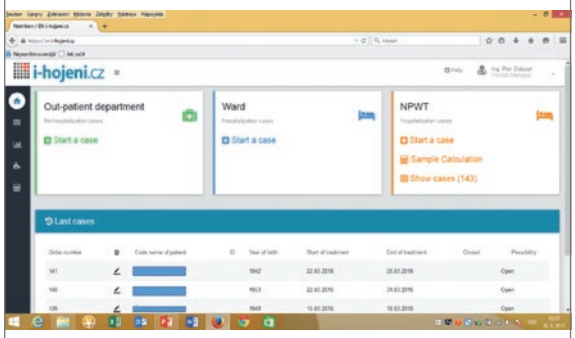

Database website: Options for adding a new case

2

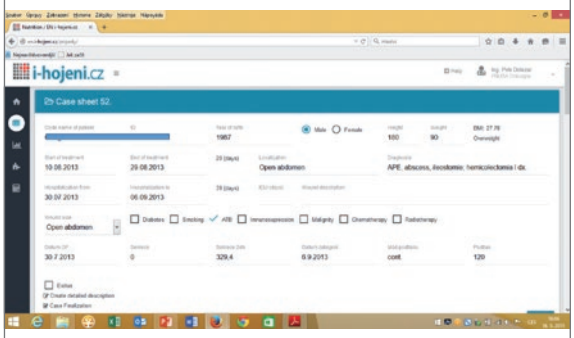

Case sheet

3

Image storage

4

Age	Number of cases	%
0-20	0	0,00%
21-40	14	9,79%
41-60	37	25,87%
61-80	69	48,25%
80 +	23	16,08%
average age	64	

Location:			
	open abdomen	25	17,48%
	abdomen	68	47,55%
	chest	16	11,19%
	lower limb	25	17,48%
	upper limb	6	4,20%
	other	3	2,10%

Number of days with NPWT application			
	1-10	43	30,07%
	11-20	56	39,16%
	21-30	30	20,98%
	30 +	14	9,79%
	median	14	days
	5percentile	1	day
	95percentile	35	days

Number of dressing changes			
	1	13	9,09%
	2	26	18,18%
	3	34	23,78%
	4	31	21,68%
	5	9	6,29%
	6 and more	30	20,98%
	median	3	dressing changes
	5percentile	1	dressing change
	95percentile	8	dressing changes

Data analysis using the database: Data from 143 NPWT patients.

5

		Age up to 60	Age 60+	p
Days of hospitalization	Median days	32	40	0,521
Number of days with NPWT application	Median days	14	14	0,51
Number of dressing changes	Median dressing changes	3	3	0,997
	Men		Women	
Days of hospitalization	Median days	34	40	0,122
Number of days with NPWT application	Median days	12	16	0,093
Number of dressing changes	Median dressing changes	3	3	0,214

Data analysis using the database: Although patients aged 60+ years, as may be expected, had a longer hospitalisation, there was no difference in the length of NPWT treatment. There was no demonstrable difference in healing or length of hospitalisation between the sexes.

6

		2012-2013	2014-2015	P
Days of hospitalization	median	40	33	0,519
Number of days of NPWT application	median	14	13	0,214
Number of dressing changes	median	4	3	0,001

Data analysis using the database: Cost reduction from 2012/13 to 2014/2015 was related to the statistically significantly decrease in the number of dressing changes required.

Advanced NPWT for infected wounds in long-term implants

Heinrich Rotering
Department of Cardiovascular Surgery, University Hospital, Muenster, Germany

Deep sternal surgical site infection after cardiac surgery is a severe complication, with an estimated incidence of 1 – 4%, a mortality rate of 15 – 40% and single case costs of 36,000 euros. In the implanted devices infections and biofilms are major problems. The standard guideline for a cardiac implantable electrophysiological device with a type I infection suggests its removal. The question is how to improve the standard treatment of these infections.
One possible solution is Zorflex dressing in combination with NPWT. This activated carbon cloth with a wool-like structure has a highly microporous structure, providing a very large surface area to take up bacteria and all types of molecules that require removal from the wound. Here, we demonstrate its successful application in three cases.

Patient anamnesis

Patient 1 was a 73-year-old male with coronary artery disease, ischaemic cardiomyopathy, severe obesity, critical illness-polyneuropathy and peripheral occlusive disease, who underwent coronary artery bypass grafting (CABG). Patient 2 suffering from diabetes mellitus and obesity was undergoing a CABG and displayed a severe reactive psychosis. Patient 3 was a 77-year-old female with mitral valve insufficiency, coronary artery disease, myocardial infarction, left bundle branch block, chronic obstructive pulmonary disease and emphysema.

Wound anamnesis

Following a CABG, patient 1 developed a superficial infection of the sternal wound with Staphylococcus epidermidis (S. epidermidis). Patient 2 developed complete sternal instability with S. epidermidis infection. Patient 3 developed a lead and pocket infection also with S. epidermidis.

Aim of the treatment

Application of the activated carbon cloth dressing Zorflex in combination with negative pressure wound therapy (NPWT) to treat wound infections in long-term implants.

Wound treatment

Patient 1 was given conventional NPWT for 1 week, after which the swab remained positive for S. epidermidis. Foam wrapped with Zorflex dressing was placed in the wound and NPWT was reapplied. After 3 days, the wound appeared perfectly clean and the swab was negative for S. epidermidis. Wiring could be left in place and the wound closed.
Patient 2 was initially given conventional NPWT for 2 days, with the wound being infected. NPWT was subsequently combined with a Zorflex dressing for 6 days. The wound appeared clean red and was negative for S. epidermidis. The wound was closed with the sternum fixed again with sternal cerclages.
Having undergone numerous major operations since 1996, Patient 3 did not want to undergo any further operation to treat the infection, particularly as the double-coil lead was well implanted and difficult to extract. Thus NPWT was applied. The atrial leads could be completely removed to allow debridement. Due to infection in the pocket the ICD unit had to be removed, leaving just the lead ends to allow complete coverage of the pocket with the Zorflex dressing. With foam on top of the dressing NPWT was applied. On completing NPWT StratticeTM tissue matrix was applied for optimal wound closure of the pocket with the leads underneath. The wound was closed and healed in a satisfactory manner.

Conclusion

The carbon cloth dressing Zorflex in combination

with NPWT is a very useful tool for treating infected wounds in long-term implants. Correct application of the dressing is mandatory and the cloth allows complete coverage of the wound, also avoiding direct foam contact particularly with the heart. The cycle length can be shortened reducing therapy costs.

Patient 2, conventional NPWT following CABG: Wound infected following 2 days of conventional NPWT.

Patient 2, completion of advanced NPWT: Following NPWT for 6 days with the foam in a Zorflex dressing, the wound is clean with healthy red tissue. The sternum device could be placed inside and the wound closed.

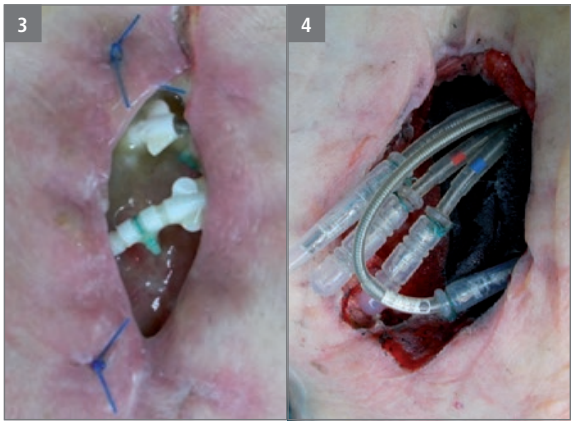

3) Patient 3: Lead infection.
4) Patient 3, ICD unit removal: Because of infection in the pocket, the ICD unit required removal. The lead ends are left in place. Foam is positioned underneath.

Patient 3, advanced NPWT: The foam within a Zorflex dressing is inserted into the pocket, the dressing covers the whole pocket.

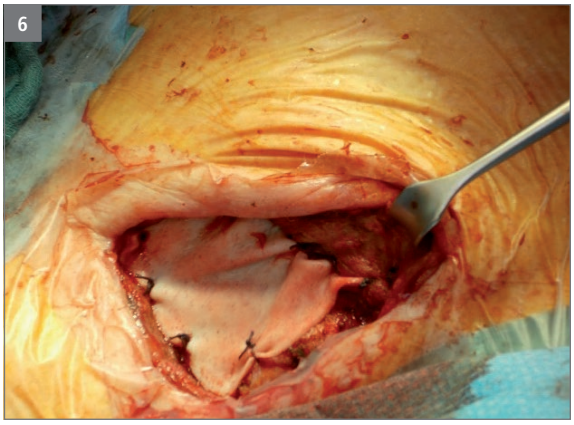

Patient 3, grafting: On completing NPWT using Zorflex dressing, the tissue is now healthy. StratticeTM is applied for optional closure. The wound is closed. Healing was satisfactory.

NPWT after vulvar carcinoma surgery

Emilie Raimond, Aurélie Pelissier, Marie Etienette Emeriau, Olivier Graesslin
Maternité Alix de Champagne, Service de gynécologie, CHU de Reims, France

Two females aged 59 and 78 years with stage IIIC and stage IB vulvar carcinoma, respectively, who displayed complications following surgery.

Patient anamnesis

Patient 1, a 59-year-old female, presented with stage IIIC vulvar carcinoma, displaying a 5-cm tumour in the major axis, located on the right labium minus. Patient 2, a 78-year-old female, presented with stage IB vulvar carcinoma with a 1.5 cm tumour present on the left labium minus. A 1 mm tumour infiltration of the urinary meatus was found. Biopsies for both patients indicated squamous cell formation and a well-differentiated carcinoma. Both patients underwent complete radical vulvectomy with bilateral inguinal lymph node dissection. In patient 1, an outlier VY was associated with the lymph node dissection. In patient 2, the dissection was accompanied by urinary and skin anastomoses.

Wound anamnesis

Patient 1 developed a Pseudomonas aeruginosa infection on day 3 and wound breakdown on day 5. Patient 2 suffered wound breakdown on day 13, with necrotising cellulitis, which was also found in the inguinal areas.

Aim of the treatment

The application of negative pressure wound therapy (NPWT) to accelerate wound healing when local care of wound complications following vulvar carcinoma surgery is unsatisfactory.

Wound treatment

Patient 1 received antibiotic treatment for the infection on day 3 and after wound breakdown on day 5 underwent local care with twice-daily calcium alginate applications. NPWT was commenced on day 18 due to the failure of local care. In the vulvar region, a urinary catheter was inserted and a hole was made around the anus for defecation. Two further interfaces were used, one for the vagina and one for the healthy skin around the wound to allow NPWT application without damaging adjacent organs. The NPWT was changed every 2 days, with gradual filling of the lost tissue. On day 38, NPWT was stopped after 20 days of use and local care with the application of calcium alginate was recommenced. A skin graft was performed on day 45, after which NPWT was reapplied at –80 mmHg. Total skin defect closure was obtained in 40 days. Patient 2 underwent revision surgery, received triple antibiotic therapy (tazocillin, vancomycin, amikacin) and hyperbaric chamber treatment for the necrotising cellulitis. Following this treatment, the patient had a major skin defect, for which local care was commenced with calcium alginate, changed twice daily. The results were unsatisfactory, and NPWT was commenced on day 25. There was gradual filling of the areas of lost tissue. On day 64, a skin graft was performed and NPWT was applied at –80 mmHg. Total skin defect closure occurred after 40 days.

Conclusion

NPWT is an essential tool for the treatment of wound breakdown following vulvar cancer surgery. It provides more rapid healing and is gentler for the patient than local care, and reduces the number of procedures in this difficult to access area.

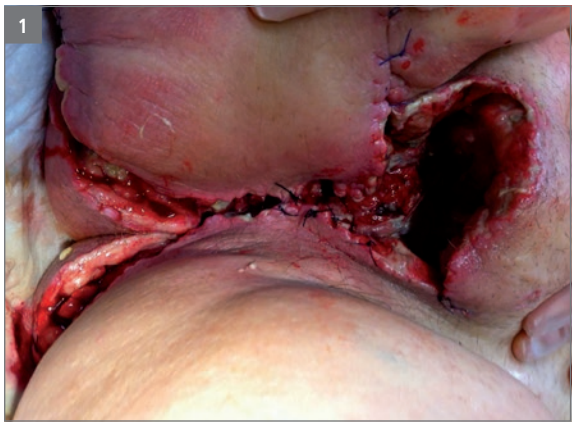

Patient 1: Inadequate results following antibiotic treatment of wound infection and local care of the wound breakdown after complete radical vulvectomy with bilateral inguinal lymph node dissection and associated outlier VY.

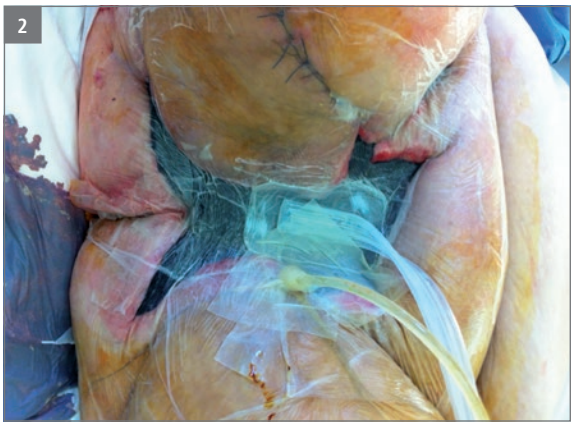

Patient 1, NPWT: On day 18 post surgery, NPWT was commenced, with a urinary catheter and two interfaces, for the vagina and for the healthy skin around the wound.

Patient 1, day 85: After skin grafting on day 45 and further NPWT, total closure of the skin defect was achieved.

Patient 2, day 13: Wound breakdown with necrotising cellulitis.

Patient 2, day 25: Following revision surgery, triple antibiotic therapy and hyperbaric chamber treatment, the treatment of the major skin defect for the necrotising cellulitis using calcium alginate was unsuc-ces-sful, and so NPWT was commenced.

Patient 2, day 104: After a skin graft on day 64 and further NPWT at –80 mmHg, total closure of the skin defect was obtained in 40 days.

Application of NPWT in sealing of body cavities

P. Ihle, S. Weise
Department of General, Abdominal, Thoracic Surgery and Proctology, Hufeland Clinic GmbH, Mulhausen, Germany

Three examples of body cavity treatment using negative pressure wound therapy (NPWT) in proctology (rectal abscess), orthopaedics (fall-induced haematoma in the knee) and abdominal surgery (septic shock and small intestine obsolete perforation).

Patient anamnesis

Patient 1 was a young male who suffered anal pain for 2 weeks and complained of fever and chills. Laboratory results indicated inflammatory characteristics. Patient 2 was a female who had fallen at home following knee-replacement surgery. Patient 3 was a young male who had suffered blunt abdominal trauma in his transport job.

Wound anamnesis

Patient 1 had a spontaneously perforated abscess, with the abscess itself encompassing the entire rectum. The haematoma found in the knee of patient 2 was drained for several weeks but there was no tendency towards healing. Patient 3 was admitted 3 days after the accident with septic shock and an obsolete perforation of the small intestine. Diffuse peritonitis and situs were present together with fibrin layers throughout.

Aim of the treatment

The application of NPWT to different body cavities to induce primary healing.

Wound treatment

Patient 1 underwent a sparing necrectomy, filling the wound cavity with foam. Drainage tubes were connected to a source applying NPWT. The sponge was replaced four times under anaesthesia, continually reducing the foam size. The patient was fully mobilised, ate a normal diet and had regular bowel movements. Outpatient treatment was initiated after 4 weeks. At the 6-month check-up, there was no stoma and healing was complete. Patient 2 underwent debridement followed 3 days later by the application of NPWT. Perforated drainage tubing was placed between two layers of foam and the whole inserted in the wound cavity. The drainage tubes were channelled, with the sponge / tube system connected to a negative pressure source to initiate NPWT. The foam was changed five times under anaesthetic. During this time, the patient became fully mobilised. Secondary suturing was applied and outpatient treatment was started after 24 days with primary healing of the wound. Patient 3 underwent a laparotomy and resection of the small intestine with lavage followed by closure for 12 hours for stabilisation. Following a repeat laparotomy, drainage tubing within two foam layers was inserted into the abdomen, the abdomen wall closed using fixed sutures, the channelling drainage tubes connected to a negative pressure source and NPWT was commenced. The foam was changed five times under anaesthetic and an anastomosis of the small intestine was performed after the second change. On completion of the fourth change (16 days post-surgery), the abdomen, including the fascia, were closed and the patient was discharged after 24 days in good health with a healed wound. No hernia was present at the 4-month check-up. We have treated 28 patients using 78 surgical procedures in the last 5 years with this system, achieving primary healing in each case, avoiding complications (e.g. fistula, bleeding and compartment syndrome) and reducing the occurrence of hernia. Direct contact of the sponge with the organ was possible without complications by applying lower pressure and, when necessary, after stopping suction, instilling water for approximately 30 minutes to make removal of the foam easier. The foam was changed every 3 or 4 days.

Conclusion

The advantages of applying NPWT in the treatment of body cavities: primary wound healing is possible; reduced occurrence of retraction of fasciae;

reduced occurrence of incisional hernia; no maceration of the skin surrounding the wound.
It is essential that a lower pressure is applied when vacuum sealing body cavities, with a negative pressure of 50 – 75 mmHg in the abdominal cavity and 100 – 125 mmHg in a soft-tissue cavity, which allows direct contact between the sponge and the organ without complications.

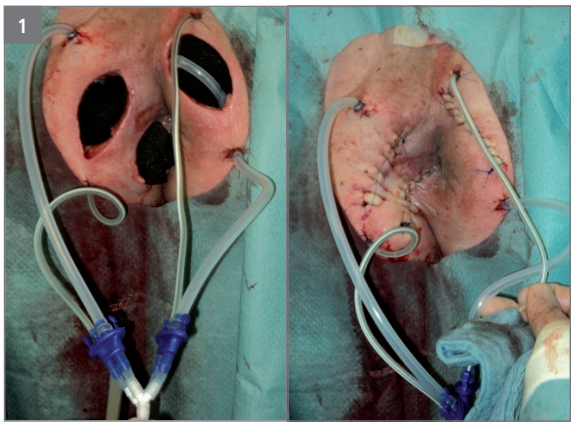

Patient 1, rectal abscess: Following a sparing necrectomy of a spontaneously perforated abscess of the rectum, foam with drainage tubing is inserted into the wound cavity (left) and temporarily sealed (right) before applying NPWT with four foam changes. Outpatient treatment started after 4 weeks, with complete healing by 6 months.

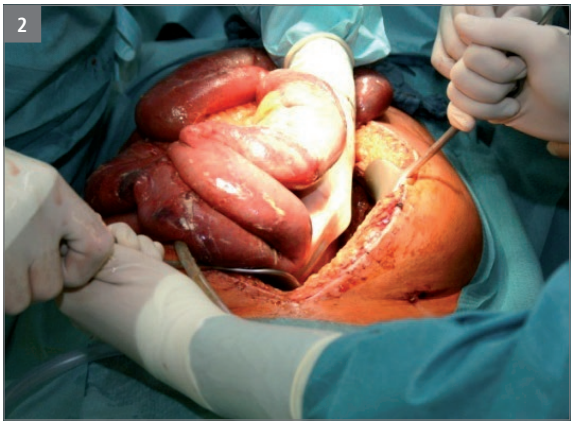

Patient 3, blunt abdominal trauma: Diffuse peritonitis following perforation of the small intestine, with situs after abdominal lavage.

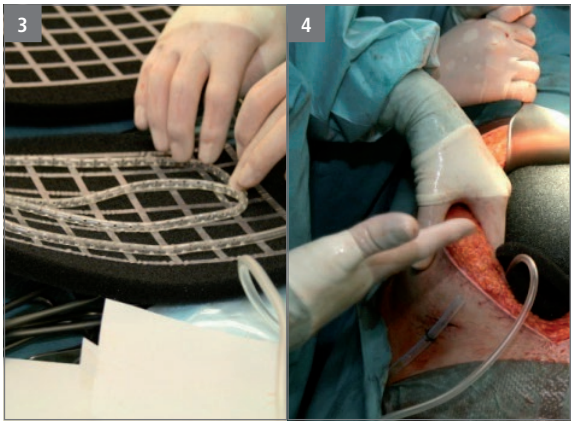

3) Patient 3, sponge system configuration: Perforated drainage tube placed between two layers of sponge.
4) Patient 3, preparation for NPWT: Insertion of the sponge system into the abdomen.

Patient 3, preparation for NPWT: Abdominal wall closed using fixed sutures and channelling of drainage tubes.

Patient 3, completion of NPWT: Following four NPWT treatment cycles, the abdominal cavity is clean. The abdomen and fascia are closed. The patient was discharged after 24 days and in good health after 4 months without hernia.

Closed-wound NPWT in below-knee amputation

G. Maxant, C. Deharvengt
Department of Vascular Surgery, Centre Hospitalier de Haguenau, France

Retrospective study of negative pressure wound therapy (NPWT) treatment of 19 consecutive cases of below-knee amputation (BKA) from October 2013 to December 2014.

Patient anamnesis

There were 11 males and 8 females of mean age 72.5 years, with 2 patients receiving peritoneal dialysis. Indications were 11 non-revascularisable critical ischemia, 4 non-viable acute ischemia, 3 chronic osteomyelitis of the mid-foot and 1 chronic infection of a previous BKA. An occlusion of the superficial femoral artery was found in 10/19 patients.

Wound anamnesis

Fifteen patients had chronic wounds, of which 11 were acutely septic.

Aim of the study

To determine whether NPWT application to the BKA stump can improve the wound-healing rate and reduce the need for above-knee amputation (AKA). The healing status was considered on days 5 and 60.

Wound treatment

BKA was performed with primary closure by posterior flap (except one case: skew amputation due to the extension of the necrosis). Closure was obtained via three planes (aponeurosis, subcutaneous, skin) of interrupted sutures., with a sub-aponeurotic drainage via a Redon. NPWT was applied to the closed wound using the Vivano system. Horseshoe-shaped foam was applied with standard fixation. There was interposition of an impregnated gauze dressing. Continuous pressure was applied at –110 mmHg. The Redon was removed on day 2 post-surgery and the NPWT was ceased on day 5, transferring the patients to a dedicated rehabilitation unit whenever possible. A dialysis patient died of massive infarction on the night following BKA. There were two further deaths in short-term; one on day 7, due to cardiac insufficiency and contralateral critical ischemia, the second on day 30 of a new embolic event, neither of which were linked to the method. There were very few complications, with 2 cases of blisters without clinical significance. The drained volume was low in all but one case, the exception being 400 mL in a patient with non-viable acute ischemia, without residual haematoma. Wound closure occurred on day 5 for 17/18 cases. The remaining patient showed cutaneous and muscular necrosis with local Staphylococcus aureus infection. Surgical revision was performed on day 6 with conventional 'open-wound' NPWT and intravenous followed by enteral antibiotic therapy. This wound displayed secondary closure at 1 month, with knee conservation allowing prosthesis fitting and a good functional result. Of the 16 survivors on day 60, 12 showed primary wound closure while 1 patient displayed closure after surgical revision (cf supra). Three patients had a superficial defect without requiring revision: the knee was preserved in all this patients after standard local care procedures.
Twelve patients received a prosthesis; the four exclusions being for old age, dementia (2) and cumulated comorbidities (polyarthritis and denutrition). All the patients who could walk before BKA could, with a single exception (dementia), still walk after rehabilitation. There was functional amelioration in 2 cases.

Conclusion

The knee was preserved in all 16 survivors, with no clinically significant complications, compared to an AKA rate of 22–50% in the literature. The mortality of 3/19 was similar to the rate observed in AKA patients. The treatment was reproducible with no specific skill or devices ('off the shelf' Vivano unit and foam) required and expected costs of approxi-

mately 70 Euros/5 days, with a probable reduction overall in additional costs through a lower complication rate. A larger multicentre study is required to confirm these results and it is an open question as to whether this procedure is applicable to trans-metatarsal amputation and other high-risk surgical wounds, including coronary artery bypass graft, obese patients and complex ankle and foot surgery.

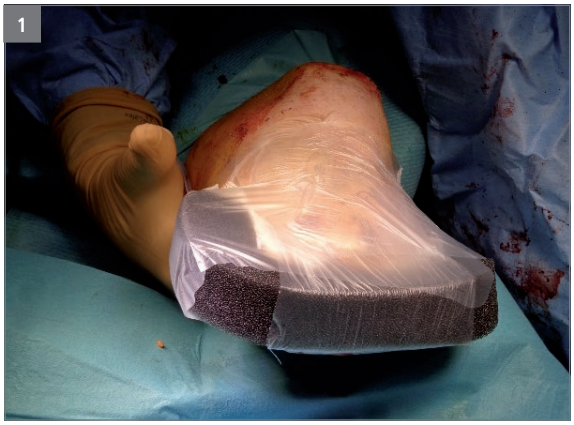

NPWT: Horseshoe-shaped foam applied with standard fixation and interposition of a fat dressing.

Day 5: On completion of NPWT: aspect of the wound 5 days after trans-tibial amputation.

NPWT of soft-tissue infection after total knee arthroplasty

Rui Pedro Borlido Escaleira, Pedro Miguel Dantas Costa Marques, Marilia Cardoso, Alberto Midões
Surgery Department/Wound Treatment, ULSAM, Portugal

A 68-year-old female patient developed a surgical-site infection with cellulitis after a total knee arthroplasty for limiting gonarthrosis.

Patient anamnesis

A 68-year-old female patient with hypertension and type II diabetes developed surgical-site infection with cellulitis following total knee arthroplasty.

Wound anamnesis

The patient received prophylactic antibiotic treatment for 2 days post-surgically. Surgical site infection with cellulitis was diagnosed 24 days post-surgically. Methicillin non-resistant Staphylococcus aureus was present.

Aim of the treatment

The use of negative pressure wound therapy (NPWT) for local, regional and systemic control of the infection, exudate management, closure of the communication between the surface and the joint cavity and wound-bed preparation for surgical reconstruction.

Wound treatment

Broad-spectrum antibiotics were applied. Skin necrosis of the knee developed, however, with progression of inflammatory analytical parameters leading to fever but without shock. On day 30, there was infection of the deep layers at the surgical site, with the assumption of a risk of colonisation or infection with peri-prosthetic involvement. Very aggressive wound debridement was performed in the operating theatre. No abscess was present, but there was infection of the deep layers and a communicating hole with the articular cavity with serous drainage fluid was found. The dressing characteristics required were good exudate management, bioburden reduction and removal of pro-inflammatory mediators, as well as the creation of a pressure gradient in the direction of the wound. The main goals were to control infection and consequently reduce the risk of colonisation of the prosthetic material, which would otherwise lead to its removal, and to promote good wound healing to allow skin grafting. NPWT was applied using polyurethane foam with a continuous pressure of –125 mmHg, without a layer between the wound and foam. No necrotomy was performed between dressing changes. After 5 days, the inflammatory signs were absent but the hole remained, with serous liquid draining from the cavity. After 10 days of NPWT, the oedema had reduced, there was less drainage and some granulation tissue was present. On day 15 of treatment, there was complete granulation of the hole, such that the hole was no longer present, and there was no drainage. The patient received skin grafting in the plastic surgery department and full mobility was subsequently restored to the knee.

Conclusion

The first aim of NPWT treatment, to control infection, was achieved after 5 days and the remaining end-points to prepare the wound bed for skin grafting were obtained after 15 days, with subsequent recovery of full mobility in the knee. The Vivano system proved effective in obtaining the pre-established end-points in the shortest time.

Day 30 post-surgery: Surgical site infection with cellulitis.

Day 30 post-surgery (NPWT day 0): Following aggressive debridement, infection of the deep layers was found, together with a communicating hole with the articular cavity (arrow), containing serous fluid.

NPWT: Applied continuously at –125 mmHg.

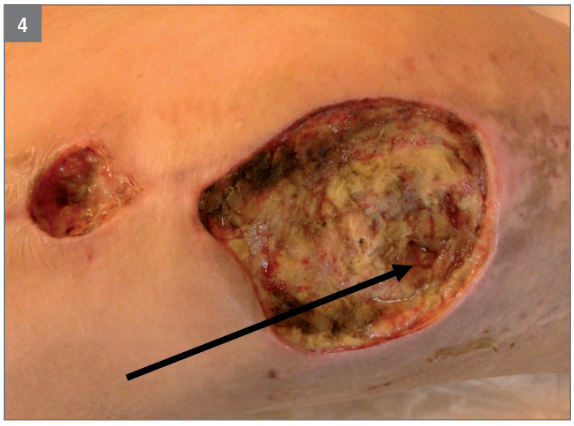

NPWT day 5: Inflammatory signs were absent but the hole remained (arrow), with serous liquid draining from the cavity.

NPWT day 10: Reduction of the oedema and drainage, with some granulation tissue present (arrow indicates the hole).

NPWT day 15: Granulation completely fills the hole (arrow) and there was no drainage fluid. The patient was sent for skin grafting, which was successful.

Is NPWT cost-effective?

Joerg Linder
PAUL HARTMANN AG, Heidenheim, Germany

When contemplating the issue of cost regarding negative pressure wound therapy (NPWT), those responsible for the hospital budget only consider the unit cost, particularly when comparing the NPWT equipment with, for example, gauze pads. When thinking in terms of unit cost alone, hidden costs, including wound-dressing changes, hospitalisation and follow-up care due to inadequate treatment, are not considered. Therefore, unit cost alone provides an incomplete picture as to whether NPWT can save costs within the overall budget.

Aim of the study

To look for evidence for cost savings from three clinical trials and to consider whether NPWT is a main cost driver in three cost-calculation studies from three countries.

Evidence for cost saving through improved healing

The Dutch prospective randomised controlled trial of Vuerstaek et al. (J. Vasc. Surgery, 2006, 44, 1029 – 1037) considered 60 patients with chronic leg ulcers for >6 months, for which surgical operations had been exhausted. Inpatient NPWT was compared to standard wound treatment (SWT) with alginates and hydrogels for complete healing. The median healing time was reduced from 45 days for SWT to 29 days for NPWT. Both treatments were used until there was 100% wound-bed granulation, followed by full-thickness punch graft. NPWT healing time was again shorter than for SWT, at 7 and 17 days, respectively. The shorter healing time with NPWT led to large cost savings, even when comparing wound care cost without including the longer hospitalisation. In a similar trial in the Netherlands, Moues et al. (J. Wound Care, 2005, 14, 224 – 227) compared NPWT with conventional therapy (CT) with moist gauze for full-thickness wounds in 54 patients. The end-point of a healthy granulating wound bed for surgical grafting was reduced from 9.9 days with CT to 7.2 days with NPWT. Despite the more costly NPWT device compared to the cheap moist gauze comparator (unit cost), there was no statistically significant difference in the overall cost. In a retrospective study of hospital patient medical documentation in Poland, Banasiewicz et al. (Negative Pressure Wound Therapy 2014, 1, 39 – 47) compared NPWT in 17 patients with standard therapy (ST) in 20 patients. The hospital stay was reduced from 43 days with ST to 26 days with NPWT. With NPWT, the stay in intensive care was also shorter and the mortality rate was reduced from 45% to 18%. The mean direct patient cost was one third lower for NPWT (€11,739) compared to ST (€17,400).

NPWT as the main cost driver

Three single-centre retrospective studies based on medical documentation files are considered here. In France, Bernard et al. (J. d. Plaies et Cicatrisations, 2014, 92, 22) reported that for all indications in 22 patients, NPWT accounted for only 7% of the total patient refund for hospital costs obtained via the French DRG (general health system). Furthermore, 87% of these patients achieved effective wound healing. Svenson et al. (Eur. J. Vasc Endovasc Surg, 2008, 36, 84-89), in Malmo, Sweden, found that, for inguinal peri-vascular surgical site infections of 33 patients, NPWT accounted for only 3% of the total inpatient cost. Following the patients in the outpatient sector, 82% of the wounds healed within 55 days. Because funding is available for outpatient NPWT treatment, 13 patients continued with home treatment, saving on inpatient costs. Kolios et al. (GMS German Medical Science

2010, 8, ISSN 1612-3174) in Goettingen, Germany, reported that, for traumatically acquired wounds in 67 patients, a cost-accounting system closely resembling the German DRG system for hospitalization care showed that NPWT represented only 6% of the total cost despite the patients having a high comorbidity level, while labour and infrastructure accounted for >80%.

Conclusion

When looking beyond the unit-price comparison, NPWT can clearly lead to cost savings in a clinical context in terms of the total costs. However, to achieve savings, NPWT must be applied to the appropriate patients. In less difficult wounds, alternative cheaper products can provide equally effective treatment. When considering the individual patient, NPWT does not make the cost more expensive, but rather the long hospitalisation because of a difficult wound. The physician should not only emphasise the clinical benefits of NPWT but also, from the point of view of those managing the hospital budget, what costs savings are possible. Therefore, there is a need to balance the cost with the medical requirement of the individual patient to achieve sustainable and appropriate healthcare.

1

Unit cost versus total cost: While the unit cost of NPWT may be greater compared to simple dressings, this misses the big picture of the hidden costs, where savings can be made using NPWT.

2

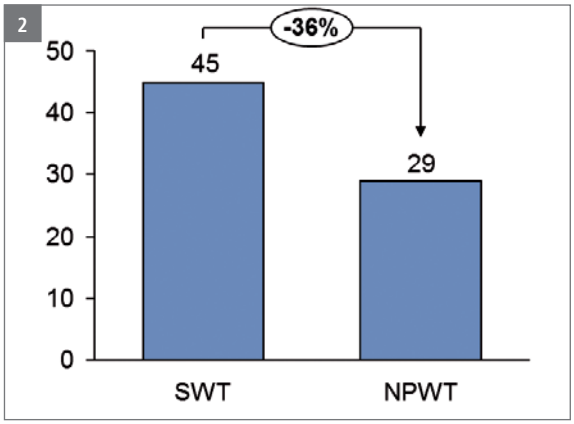

Chronic leg ulcers: Median healing time in days for chronic ulcers >60 days old, which received standard wound treatment (SWT) of alginates and hydrogels or NPWT (data taken from Vuerstaek et al. J. Vasc. Surgery, 2006, 44, 1029 – 1037).

3

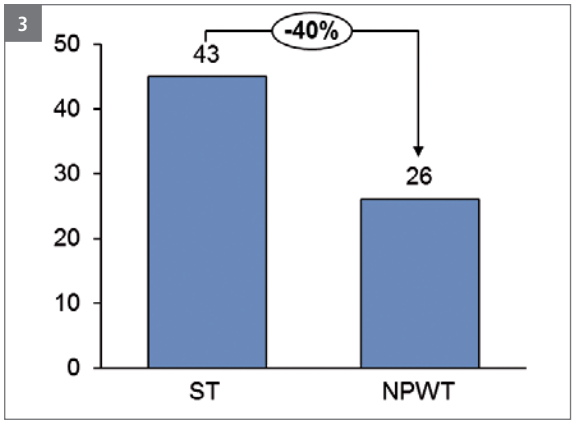

Open abdomen: Mean hospital time in days for open abdomen comparing standard treatment (ST) with NPWT (data taken from Banasiewicz et al., Negative Pressure Wound Therapy 2014, 1, 39 – 47).

4

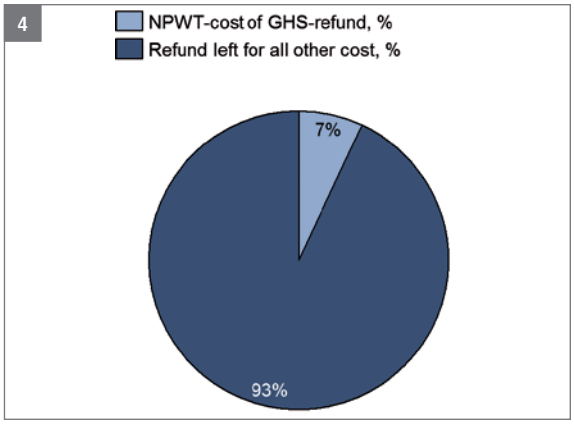

NPWT costs in France: Calculation for all indications of the direct cost of NPWT equipment (pump and disposables) compared to the general health system refund (data taken from Bernard et al., J. d. Plaies et Cicatrisations, 2014, 92, 22).

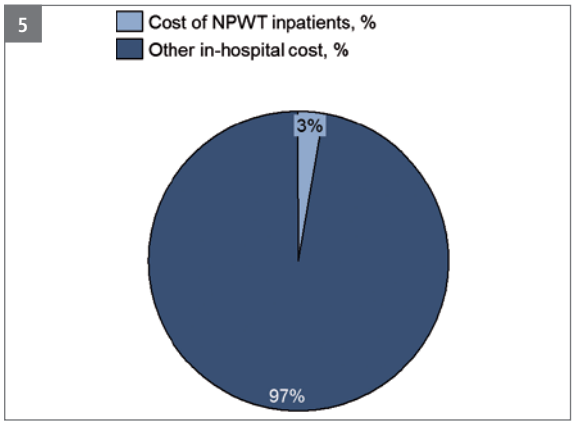

NPWT costs in Sweden: Calculation of the direct cost of medical treatment in hospital for inguinal peri-vascular surgical site infections (data taken from Svenson et al., Eur. J. Vasc Endovasc Surg, 2008, 36, 84 – 89).

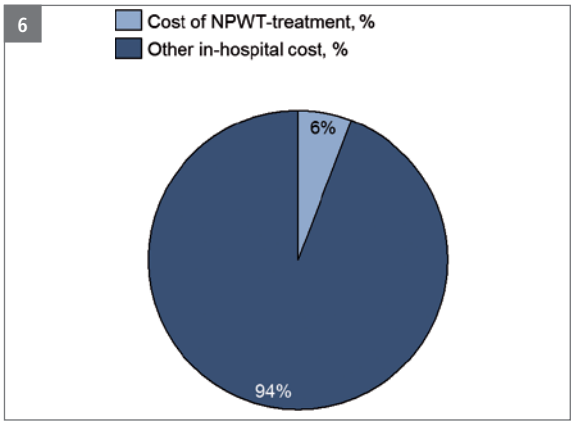

NPWT costs in Germany: Calculation of the direct cost of medical treatment in hospital for traumatically acquired wounds (data taken from Kolios et al., GMS German Medical Science 2010, 8, ISSN 1612-3174).

Notes

Notes

Going further
for health

PAUL HARTMANN AG
Paul-Hartmann-Straße 12
89522 Heidenheim
Germany

Visit our website:
www.vivanosystem.info

(01/16)